



**PATIENT**

Stella Trugyan

**PRESENTING CLINICAL SIGNS**

History: Intermittent collapse. Tachycardia.

**SPECIES**

Feline

**BREED**

Tabby

**SEX**

Female Spayed

**AGE**

5 years

**WEIGHT**

12lbs

**HOLTER MONITOR FINDINGS AND RHYTHM ASSESSMENT**

Time analyzed	21:08h
Mean heart rate	175bpm
Maximum heart rate	284bpm
Minimum heart rate	104bpm
VPCs	0
APCs	0

Interpretation: Underlying normal sinus rhythm with appropriate rate variation. A brief period of sinus tachycardia is noted (1:00am) without explanation which is of little significance. No premature beats, pauses or other issues are identified.

Rhythm diagnosis: Sinus rhythm with appropriate HR variation. Brief sinus tachycardia.

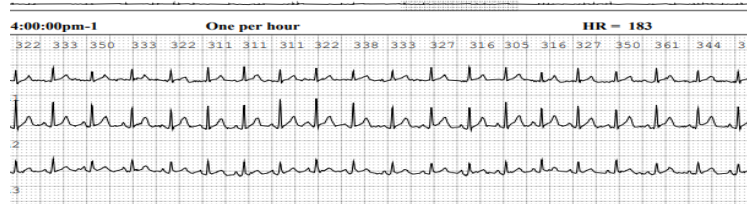
**RECOMMENDATIONS**

Normal tracing. Collapse due to arrhythmias is exceedingly rare in cats, particularly given a normal tracing. Consider full systemic evaluation including an echocardiogram as the next step. Additionally, causes of sinus tachycardia should be considered such as anemia, dehydration, etc.

**INTERPRETED BY**

Maggie Machen Lamy,  
DVM, DACVIM  
(Cardiology)

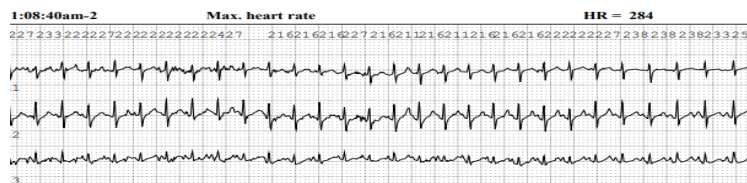
**IMAGES**



NSR

**IMAGING PERFORMED BY**

Ashely



Sinus tachycardia

**HOSPITAL NAME**

Rockaway Animal  
Hospital

**REFERRING VET**

Dr. Maniar

The information and recommendations provided are based on the images presented by the referring veterinarian. No evaluation can be communicated regarding pathology that was not visible in the image/video clips provided.

**INVOICE**

26777

Thank you for this referral. This report was generated using transcription software, and minor dictation errors may be present. If the clinical or image interpretation does not parallel your findings or if I can be of any further assistance, please contact me.

**DATE**

10/6/22

Maggie Machen Lamy, DVM  
Diplomate of the American College of Veterinary Internal Medicine (Cardiology)  
info@sonopath.com